

Spontaneous coronary artery dissection involving both coronary arteries in an individual with Loeys-Dietz syndrome

Kornelia Rynkiewicz^{1,A,C-D}, Łukasz Kalińczuk^{1,A-F}, Wiktor Skotarczak^{1,D-E}, Michał Świerczewski^{1,A-B,D-E}, Kamil Zieliński^{1,D-E}, Rajmund Bobrowski^{1,E}, Ilona Michałowska^{2,E}, Zofia Bilińska^{3,E}, Marcin Demkow^{1,B-C,E}

A - Research concept and design, B - Collection and/or assembly of data, C - Data analysis and interpretation, D - Writing the article, E - Critical revision of the article, F - Final approval of article

1 Institute of Cardiology, Department of Coronary and Structural Heart Diseases

2 Department of Radiology, Institute of Cardiology Warsaw

3 Unit for Screening Studies in Inherited Cardiovascular Diseases Institute Cardiology Warsaw

Address for correspondence:

Łukasz Kalińczuk, Institute of Cardiology, Department of Coronary and Structural Heart Diseases
email: lukasz.kalinczuk@gmail.com

Wiktor Skotarczak, Institute of Cardiology, Department of Coronary and Structural Heart Diseases
email: wiktorskoti@wp.pl

Michał Świerczewski, Institute of Cardiology, Department of Coronary and Structural Heart Diseases
email: swierczewski.michal@yahoo.pl

Kamil Zieliński, Institute of Cardiology, Department of Coronary and Structural Heart Diseases
email: kamilziel@gmail.com

Rajmund Bobrowski, Institute of Cardiology, Department of Coronary and Structural Heart Diseases
email: rajmund.bobrowski@gmail.com

Ilona Michałowska, Institute of Cardiology, Department of Coronary and Structural Heart Diseases
email: imichalowska@ikard.pl

Marcin Demkow, Institute of Cardiology, Department of Coronary and Structural Heart Diseases
email: mdemkow@ikard.pl

Received: 2019-12-30

Revised:

Accepted: 2019-12-30

Final review:

DOI: 10.24255/hbj/115998

Key words:

spontaneous coronary artery dissection, Loeys-Dietz syndrome, computed tomography

Loeys-Dietz syndrome is an autosomal dominant disorder affecting the connective tissue. It is generally characterized by aortic aneurysms, arterial tortuosity and dissections, hypertelorism, bifid/broad uvula or cleft palate and early-onset osteoarthritis.⁽¹⁾ It is now estimated that spontaneous coronary artery dissection (SCAD) is the underlying cause of 1.7% to 4% of acute coronary syndromes (ACS) and accounts for 0.5% of sudden cardiac deaths.⁽²⁻⁴⁾ Furthermore, in young women <60 years of age, SCAD accounts for 22% to 35% of ACS presentations.^(2,5,6) It has been proposed that a mutation in transforming growth factor beta receptors 1 and 2 and SMAD3 genes and a documented arterial aneurysm or dissection should suffice to establish a diagnosis of LDS.^(7,8) A 48-year-old woman with Loeys-Dietz syndrome with no aortic enlargement was admitted for scheduled diagnostics for examination of coronaries due

to nonspecific chest pain. The 12-lead ECG recorded at rest suggested myocardial necrosis of both anterior and inferior regions of the left ventricle. Echocardiography revealed mild enlargement of the left ventricle with its hypertrophy and aneurysm of the inferior wall and apical akinesia. The ECG-gated 384-row angio-CT (SOMATOM, Siemens Healthineers, Erlangen, Germany) revealed presence of dissection of the tunica intima suggesting features of SCAD recognized along the entire lengths of proximal segments of the right coronary (RCA) and the left anterior descending artery (LAD) (Figure 1a, 1b and 2a, 2 b; respectively). Finally, digital coronarography was performed using the Siemens AXIOM (1024x1024 flat panel detector) that confirmed typical features of SCAD which did not interfere with epicardial blood and tissue blood flow (normal TIMI epicardial and myocardial blood flow)

(Figure 3a, 3b; respectively). After initiation of the optimal medical therapy, the patient was discharged with no symptoms and was scheduled for routine angiography at 12-month follow-up, or whenever symptoms of angina pectoris reoccur. Spontaneous coronary artery dissection is a rare complication in patients with Loeys-Dietz syndrome that can appear due to malformation of the connective tissue in the lining of the coronary arteries. Missed diagnoses are caused by both visual

limitations of current CT and lack of clinician familiarity with the condition.⁽⁹⁾ The 1024x1024 digital coronarography (Figure 1; 1.a, 1.b, 2.a, 2.b) is a rarely used screening method. The case highlights the importance of proper angiographic screening in patients with Loeys-Dietz syndrome, especially in young females, and proves that digital coronarography is a viable method of SCAD screening.

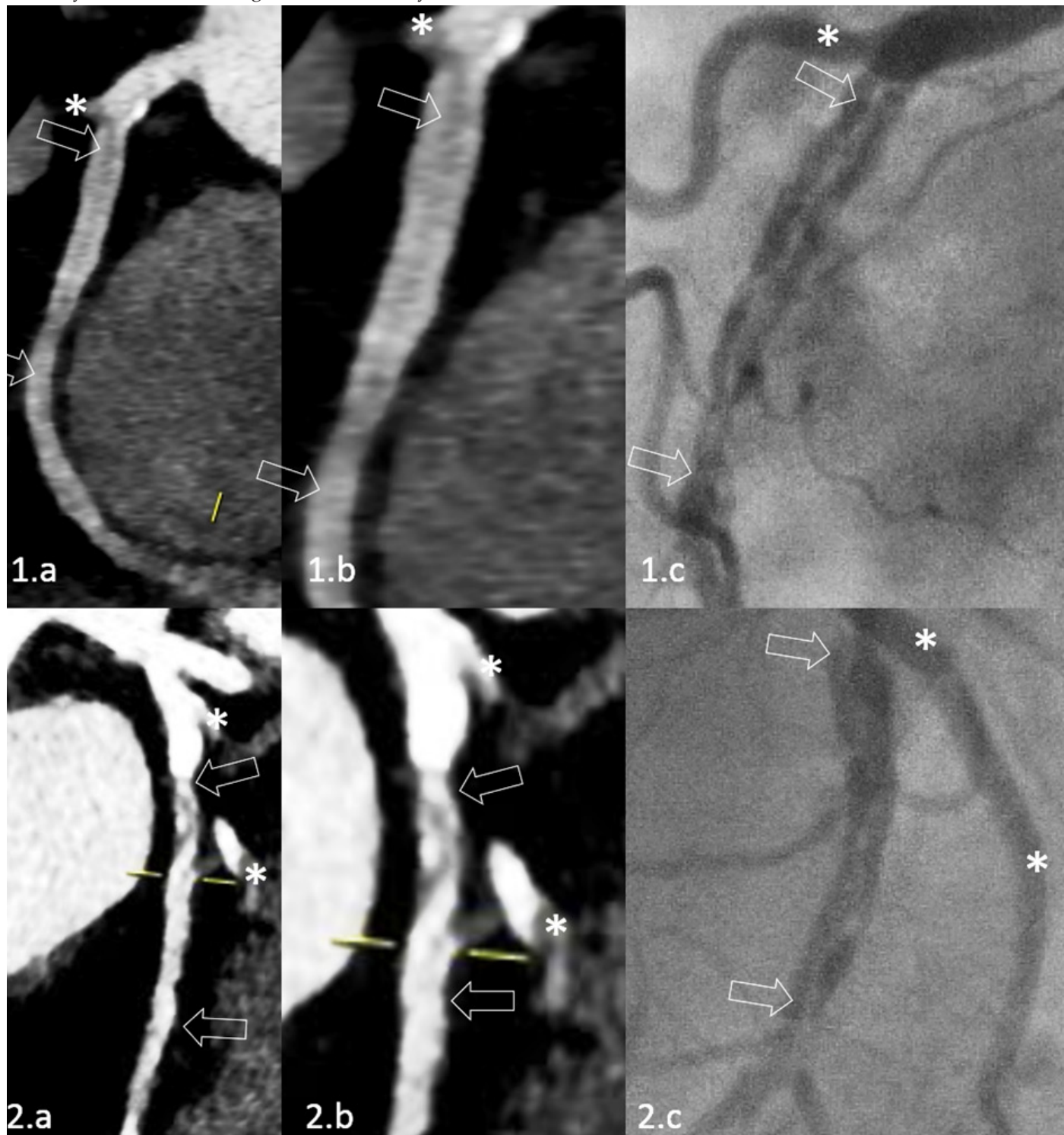


Figure 1. Computed tomography views: Panel 1a shows the RCA view with the right ventricle branch take-off indicated with a white asterisk (*); white arrows indicate the lesion length featured with the dissection of the tunica intima. Panel 1b is the magnified view (x 1.8). Panel 1c is corresponding coronary angiography with the clearly visible dissection of the inner wall of the artery (indicated with white arrows). Panel 2a shows the mid LAD with the visible IGD take-off (indicated with *) and the lesion length (indicated with white arrows) featuring typical signs of dissection of the tunica intima. Panel 2b is the magnified view (x 1.8). LAD - left descending artery, RCA - right coronary artery, IGD - 1st diagonal branch

References

1. Solomonica A, Bagur R, Choudhury T, Lavi S. Familial Spontaneous Coronary Artery Dissection and the SMAD-3 Mutation. *Am J Cardiol*. 2019 Jul 15;124(2):313-315.
2. Rashid HN, Wong DT, Wijesekera H, et al. Incidence and characterisation of spontaneous coronary artery dissection as a cause of acute coronary syndrome: a single-centre Australian experience. *Int J Cardiol* 2016;202:336–8.
3. Nishiguchi T, Tanaka A, Ozaki Y, et al. Prevalence of spontaneous coronary artery dissection in patients with acute coronary syndrome. *Eur Heart J Acute Cardiovasc Care* 2016;5:263–70.
4. Hill SF, Sheppard MN. Non-atherosclerotic coronary artery disease associated with sudden cardiac death. *Heart* 2010;96:1119–25.
5. Nakashima T, Noguchi T, Haruta S, et al. Prognostic impact of spontaneous coronary artery dissection in young female patients with acute myocardial infarction: a report from the Angina Pectoris-Myocardial Infarction Multicenter Investigators in Japan. *Int J Cardiol* 2016;207:341–8.
6. Saw J, Aymong E, Mancini J, Sedlak T, Starovoytov A, Ricci D. Non-atherosclerotic coronary artery disease in young women. *Can J Cardiol* 2014;30:814–9.
7. MacCarrick G, Black JH 3rd, Bowdin S, El-Hamamsy I, Frischmeyer-Guerrero PA, Guerrero AL, Sponseller PD, Loeys B, Dietz HC 3rd. Loeys-Dietz syndrome: a primer for diagnosis and management. *Genet Med* 2014;16:576–587.
8. Schepers D, Tortora G, Morisaki H, MacCarrick G, Lindsay M, Liang D, Mehta SG, Hague J, Verhagen J, van de Laar I, Wessels M, Detisch Y, van Haelst M, Baas A, Lichtenbelt K, Braun K, van der Linde D, Roos-Hesselink J, McGillivray G, Meester J, Maystadt I, Coucke P, El-Khoury E, Parkash S, Diness B, Risom L, Scurr I, Hilhorst-Hofstee Y, Morisaki T, Richer J, Desir J, Kempers M, Rideout AL, Horne G, Bennett C, Rahikkala E, Vandeweyer G, Alaerts M, Verstraeten A, Dietz H, Van Laer L, Loeys B. A mutation update on the LDS-associated genes TGF β 2/3 and SMAD2/3. *Hum Mutat* 2018;39:621–634.
9. Saw J, Humphries K, Aymong E, Sedlak T, Prakash R, Starovoytov A, Mancini GBJ. Spontaneous Coronary Artery Dissection: Clinical Outcomes and Risk of Recurrence. *J Am Coll Cardiol*. 2017 Aug 29;70(9):1148-1158.