

# Catheter ablation in a teenager with two arrhythmias and tachycardiomyopathy – rare clinical presentation with rapid symptoms development

B. Krzowski<sup>1</sup>, M. Peller<sup>1</sup>, R. Pietrzak<sup>2, B</sup>, Werner<sup>2</sup>, P. Balsam<sup>1</sup>, P. Łodziński<sup>1</sup>, M. Grabowski<sup>1</sup>, J. Kosiuk<sup>3</sup>, G. Opolski<sup>1</sup>

A - Research concept and design, B - Collection and/or assembly of data, C - Data analysis and interpretation, D - Writing the article, E - Critical revision of the article, F - Final approval of article

- 1) 1st Chair and Department of Cardiology, Medical University of Warsaw, Warsaw, Poland
- 2) Department of Paediatric Cardiology and General Paediatrics, Medical University of Warsaw, Warsaw, Poland.
- 3) Department of Rhythmology, Helios Clinic Koethen, Koethen, Germany.

## Address for correspondence:

Bartosz Krzowski, Medical University of Warsaw  
email: bartekkrzowski@gmail.com

Michał Peller, Medical University of Warsaw  
email: michalpeller@gmail.com

Radosław Pietrzak, Medical University of Warsaw  
email: radoslaw.pietrzak@wum.edu.pl

Bożena Werner, Medical University of Warsaw  
email: bozena.werner@wum.edu.pl

Paweł Balsam, Medical University of Warsaw  
email: pawel.balsam@wum.edu.pl

Piotr Łodziński, Medical University of Warsaw  
email: piotr.lodzinski@wum.edu.pl

Marcin Grabowski, Medical University of Warsaw  
email: marcin.grabowski@wum.edu.pl

Jędrzej Kosiuk, Department of Rhythmology, Helios Clinic Koethen, Koethen, Germany  
email: jkosiuk@hotmail.com

Grzegorz Opolski, Medical University of Warsaw  
email: grzegorz.opolski@wum.edu.pl

Received: 2019-12-17

Revised: 2019-12-31

Accepted: 2019-12-31

Final review: 2019-12-26

DOI: 10.24255/hbj/116021

## Key words:

catheter ablation, tachycardiomyopathy, multiple arrhythmia

## Abstract

Supraventricular tachycardia has several clinical manifestations, one of the most dangerous being tachycardiomyopathy, which directs the clinical approach towards catheter ablation rather than pharmacotherapy. Both an accessory pathway and focal atrial tachycardia alone are listed as risk factors for tachycardiomyopathy development. We present a case of a 17 year-old adolescent with atrioventricular re entrant tachycardia and focal atrial tachycardia, which resulted in occurrence of arrhythmia-related cardiomyopathy, and which were successfully treated with radiofrequency ablation during one procedure. All of the arrhythmia and heart failure related symptoms resolved within weeks after the catheter ablation, which confirmed these two arrhythmias as the reason for heart

remodelling. Rapid onset of symptoms requires fast action, and the electrophysiological study (EPS) with potential catheter ablation should not be postponed.

## Introduction

Clinical manifestations of supraventricular tachycardia (SVT) may range from completely asymptomatic to sudden cardiac death. Arrhythmia-related cardiomyopathy, which is also called tachycardiomyopathy (TCM), is regarded as one of the most dangerous complications connected with SVT<sup>(1)</sup>. Both an accessory pathway and focal atrial tachycardia (AT) alone are listed as TCM risk factors<sup>(2)</sup>. However, data regarding follow-up of patients with TCM, which was the result of not one, but two arrhythmias, are lacking. We present a case of a 17-year-old teenager who was admitted to our department

with symptoms of heart failure and drug-resistant tachycardia. The patient was scheduled for a catheter ablation (CA) procedure within days. Both arrhythmias were successfully treated with radiofrequency (RF) ablation during one procedure.

**Case report**

A 17-year-old patient was transferred from a district hospital with suspicion of TCM and with wide QRS complex tachycardia of 150/min. Until the index hospitalization the patient did not report any complainants regarding his health status. He was not looked after by any specialist clinic and did not take any drugs. His first specialist consultation took place just 8 days before the CA when the patient visited an adult cardiologist. Left ventricular ejection fraction (LVEF) in the echocardiography was 35% with concomitant mitral insufficiency and left atrial enlargement. The study was conducted during sinus rhythm. The diagnosis of dilated cardiomyopathy was established with the suspicion of inflammatory cardiomyopathy because of a respiratory tract infection 3 months before. The patient remained asymptomatic despite discrete dyspnoea and increased sweating, which the patient connected with overweight. High NT-proBNP level (>4000 pg/ml) was the major abnormality in the laboratory testing. The electrocardiogram (ECG) showed wide QRS complex tachycardia of 150/min with a left bundle branch block (LBBB) pattern. The treatment of heart failure consisted of lisinopril and spironolactone. In order to restore sinus rhythm adenosine i.v., amiodarone i.v., magnesium i.v. and lignocaine i.v. were administered, all without effect. Electrical cardioversion followed and restored sinus rhythm, but the effect lasted only a few minutes. The decision to conduct EPS was made at this point. At the beginning of the procedure sinus rhythm was observed with subsequent arrhythmia induction, even before coronary sinus catheterization. During programmed stimulation both atrioventricular re entrant tachycardia (AVRT) and AT occurred (Figure 1, Figure 2, Figure 3). Under the control of blood pressure values a single transeptal puncture was performed. The activation map of the mitral annulus during right ventricle stimulation was performed with a Thermo-

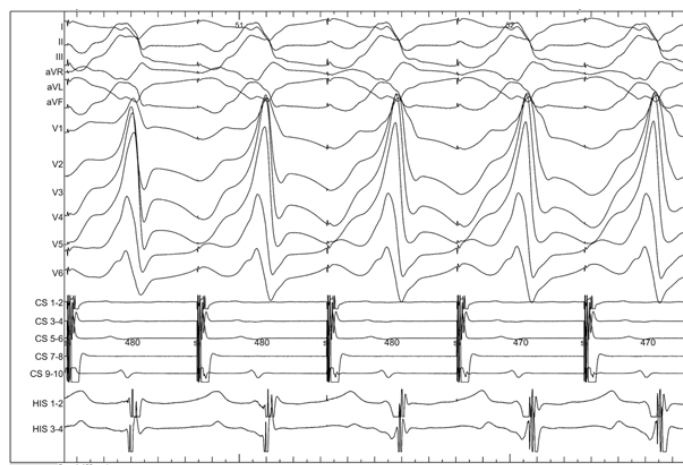


Figure 1. Coronary sinus stimulation showing wide QRS complexes with preexcitation. CS – electrode in coronary sinus, 9-10 – proximal annulus, 1-2 – distal annulus, HIS – electrode in right ventricle

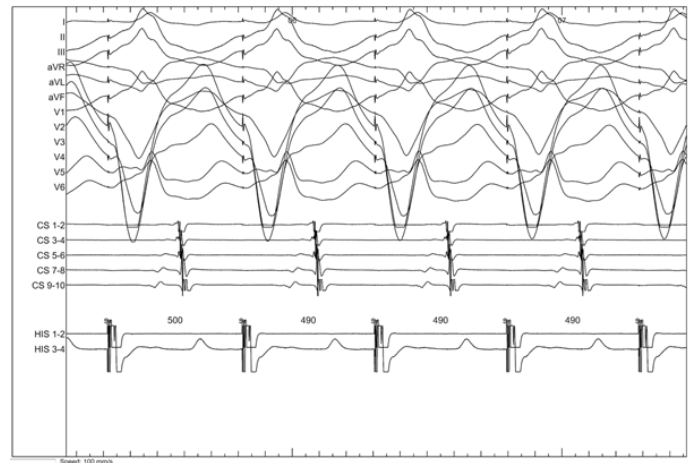


Figure 2. Right ventricle pacing showing left-sided accessory pathway conduction. CS – electrode in coronary sinus, 9-10 – proximal annulus, 1-2 – distal annulus, HIS – electrode in right ventricle

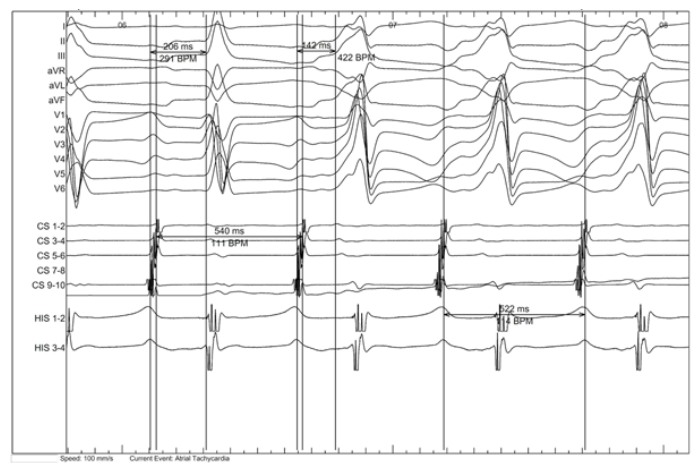


Figure 3. Atrial tachycardia with switch from physiological to accessory pathway conduction. CS – electrode in coronary sinus, 9-10 – proximal annulus, 1-2 – distal annulus, HIS – electrode in right ventricle

cool SmartTouch Cool Catheter, showing the earliest atrial activation on the lateral wall. RF ablation was performed in the area of the earliest atrial activation (Figure 4). After the successful RF applications there was no sign of retrograde

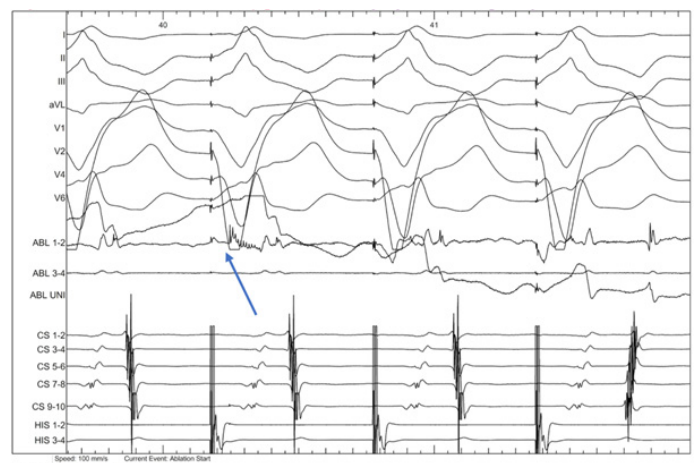


Figure 4. RF ablation of accessory pathway during right ventricle pacing. CS – electrode in coronary sinus, 9-10 – proximal annulus, 1-2 – distal annulus, HIS – electrode in right ventricle

conduction. AVRT was also not inducible. The left atrium was subsequently mapped after AT induction. Both the left and right atrium were mapped using a PENTARAY Catheter during isoprenaline infusion. The electroanatomical map showed the earliest activation on the lower part of the posterior atrial wall of the left atrium, which was ablated (Figure 5).

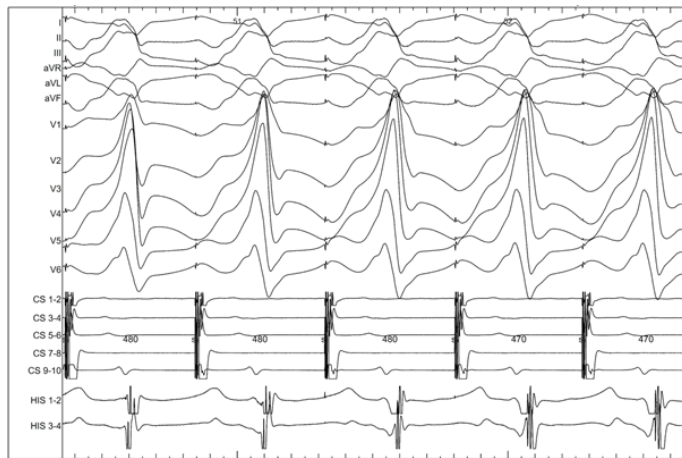

Figure 5. AT termination during RF ablation.

CS – electrode in coronary sinus, 9-10 – proximal annulus, 1-2 – distal annulus, HIS – electrode in right ventricle, an arrow indicates start of the ablation.

No arrhythmia was induced during control EPS. 15 mg of adenosine was administered, without complete heart block and without signs of an accessory pathway.

Total procedure time was 2:15 h with fluoroscopy time 5:03 min (total radiation dose: 6,86 mGy). Total number of RF applications was 14 with total application time of 10:49 min.

After the procedure sinus rhythm was maintained and the patient was transferred to the intensive care unit. Standard postprocedural echocardiography showed no effusion in the pericardial sac. The patient was discharged from the hospital without arrhythmia recurrence.

The control follow-up after 6 months showed improved heart function, with LVEF = 46%. The patient's clinical condition improved; dyspnoea and sweating disappeared. Control ECG showed sinus rhythm with heart rate of 60/min.

## Discussion

The presented case report showed successful arrhythmia-related cardiomyopathy treatment with RF ablation. TCM is an underdiagnosed disease and is related to incessant tachycardia in general with several heart rhythms as a cause. It is characterized as a reversible cause of the diastolic heart function, and CA is regarded as the main therapeutic option. There are several arrhythmias which can lead to TCM, AT being one of the main ones. Focal atrial tachycardia is not very common in the general population. A study showed the prevalence of AT to be 0.36% in asymptomatic young people and 0.46% in symptomatic ones<sup>(3)</sup>. Another study reported 1/3 of the population with AT to develop TCM<sup>(4)</sup>.

Wolf-Parkinson-White (WPW) syndrome is estimated to occur in 0.15-0.25% of the population<sup>(5)</sup>. However, the discussed patient's ECG did not show pre excitation, and the prevalence of accessory pathways, which do not manifest as a delta wave, is not known. Even though sudden onset of symptoms is not impossible for AT, it is more typical for AVRT<sup>(6)</sup>. It is not possible to establish an AP diagnosis based on the ECG without a delta wave, and EPS is a helpful tool to make a diagnosis.

Coexistence of two electrophysiological abnormalities might have been paradoxically beneficial for the patient. As both atrial and ventricular premature beats can trigger AVRT, it seems that coexistence of two arrhythmias could have exacerbated the symptoms and triggered more frequent tachycardia episodes, resulting in faster diagnosis. In the case of a slower heart rate, severe symptoms are less likely to occur. It has been established that a slower ventricular rate is associated with higher likelihood of TCM development<sup>(4)</sup>. Going further, fewer symptoms means longer time to diagnosis and potential CA. In this case, early and clinically vivid arrhythmia manifestation resulted in a rapid decision to conduct EPS. Multiple arrhythmia are not a common finding, but case reports of patients with more than one arrhythmia source have been described<sup>(7)</sup>. Similarly, a case of a patient with polymyositis and focal atrial tachycardia with three foci has been reported<sup>(8)</sup>. Another patient was described to have both AVRT and ventricular tachycardia<sup>(9)</sup>.

However, the data regarding multiple arrhythmia in a single patient leading to TCM are limited. Similarly, there is very little evidence about the success rate of the CA procedure in patients with more than one arrhythmia source. It has been stated that after the CA procedure 97% of patients restore their systolic heart function, if focal AT was established as the reason<sup>(4)</sup>. However, there is little information about follow-up of patients with more than one arrhythmia who underwent the CA procedure. Therefore, our case report shows that multiple arrhythmia related TCM can also be successfully treated in adolescents, with a good clinical follow up. LVEF is usually restored within 12 weeks; however, the data are very limited. Both a longer period to recovery and no recovery in arrhythmia-related cardiomyopathy have been discussed<sup>(10)</sup>. Interestingly, according to guidelines, in order to make a diagnosis of TCM the recovery of LV function or control of the ventricular rate should be achieved<sup>(1)</sup>. Fast action in the case of clinically rapid onset of symptoms is of utmost importance in order to prevent further systolic heart function development. Our case shows that quick action is beneficial for the patient and EPS with potential CA should not be postponed in the case of an adolescent with arrhythmia-related cardiomyopathy.

Therefore, electrophysiologists should keep in mind the possibility of multiple arrhythmia coexistence, especially in a patient with evident clinical manifestation and heart remodelling in progress.

## References

1. Brugada J, Katritsis DG, Arbelo E, Arribas F, Bax JJ, Blomstrom-Lundqvist C, Calkins H, Corrado D, Deftereos SG, Diller GP, Gomez-Doblas JJ, Gorenek B, Grace A, Ho SY, Kaski JC, Kuck KH, Lambiase PD, Sacher F, Sarquella-Brugada G, Suwalski P, Zaza A, Group ESCSD. 2019 ESC Guidelines for the management of patients with supraventricular tachycardia. The Task Force for the management of patients with supraventricular tachycardia of the European Society of Cardiology (ESC). *Eur Heart J*. 2019.
2. Ellis ER, Josephson ME. What About Tachycardia-induced Cardiomyopathy? *Arrhythm Electrophysiol Rev*. 2013;2(2):82-90.
3. Poutiainen AM, Koistinen MJ, Airaksinen KE, Hartikainen EK, Kettunen RV, Karjalainen JE, Huihuri HV. Prevalence and natural course of ectopic atrial tachycardia. *Eur Heart J*. 1999;20(9):694-700.
4. Medi C, Kalman JM, Haqqani H, Vohra JK, Morton JB, Sparks PB, Kistler PM. Tachycardia-mediated cardiomyopathy secondary to focal atrial tachycardia: long-term outcome after catheter ablation. *J Am Coll Cardiol*. 2009;53(19):1791-7.
5. Krahn AD, Manfreda J, Tate RB, Mathewson FA, Cuddy TE. The natural history of electrocardiographic preexcitation in men. The Manitoba Follow-up Study. *Ann Intern Med*. 1992;116(6):456-60.
6. Thavendiranathan P, Bagai A, Khoo C, Dorian P, Choudhry NK. Does this patient with palpitations have a cardiac arrhythmia? *JAMA*. 2009;302(19):2135-43.
7. Wang Z, Ma J, Ying Z, Bian C. Kill two birds with one stone: curing accessory pathways and premature ventricular contractions with one ablation. *Clin Case Rep*. 2016;4(6):572-5.
8. Yazaki K, Enta K, Kataoka S, Kahata M, Kumagai A, Inoue K, Koganei H, Otsuka M, Ishii Y. Focal right atrial tachycardia with three foci in a patient with polymyositis. *J Cardiol Cases*. 2017;16(4):134-7.
9. Washizuka T, Niwano S, Tsuchida K, Aizawa Y. AV reentrant and idiopathic ventricular double tachycardias: complicated interactions between two tachycardias. *Heart*. 1999;81(3):318-20.
10. Martin CA, Lambiase PD. Pathophysiology, diagnosis and treatment of tachycardiomyopathy. *Heart*. 2017;103(19):1543-52.