

Zero-fluoroscopy approach for catheter ablation of left-sided slow-fast AV nodal reentrant tachycardia

Aleksandra Świętoniowska-Mścisz^{1,A-F}, Michał Chrabąszcz^{2,A,C,E-F}, Janusz Śledź^{2,A,C,E-F}, Renata Korpak-Wysocka^{3,A,C,E-F}, Sebastian Stec^{2,4,A-F}

A - Research concept and design, B - Collection and/or assembly of data, C - Data analysis and interpretation, D - Writing the article, E - Critical revision of the article, F - Final approval of article

1. Subcarpathian Voivodeship Hospital, Krosno, Poland
2. ELMedica EP-Network, Kielce, Poland
3. Dept of Cardiology, Intercard, Nowy Sacz, Poland
4. Chair of Electroradiology, Faculty of Medicine, University of Rzeszow, Rzeszow, Poland

Address for correspondence:

Aleksandra Świętoniowska-Mścisz, Subcarpathian Voivodeship Hospital, Krosno, Poland
email: a.swietoniowska@gmail.com

Michał Chrabąszcz, ELMedica EP-Network, Kielce, Poland
email: samsung1@o2.pl

Janusz Śledź, ELMedica EP-Network, Kielce, Poland
email: januszsledz@gmail.com

Renata Korpak-Wysocka, Department of Cardiology, Intercard, Nowy Sacz, Poland
email: r.korpak-wysocka@intercard.net.pl

Sebastian Stec, ELMedica EP-Network, Kielce, Poland, Chair of Electroradiology, Faculty of Medicine, University of Rzeszow, Rzeszow, Poland
email: smstec@wp.pl

Received: 2018-02-16

Revised:

Accepted: 2018-06-16

Final review: 2018-02-18

DOI: 10.24255/hbj/92346

Key words:

ablation, AV nodal reentry, fluoroscopy, exposure, left atrial septum

Abstract

Typical slow-fast AV nodal reentrant tachycardia (AVNRT) catheter ablation (CA) of the slow pathway (SP) within the right-sided triangle of Koch is the gold standard procedure. There are, however, rare (1-2%) cases of left-sided AV connections that require a different approach to modify the reentry circuit and ablate the SP. [1-3]

We report a case of slow-fast AVNRT refractory to medical therapy and standard right-sided ablation. Retrograde

zero-fluoroscopy (ZF) mapping of the septal mitral annulus and left-sided applications achieved noninducibility and no recurrences. To our knowledge this is the first case report of zero-fluoroscopy ablation of left septal slow-fast AVNRT. Moreover, use of the ZF approach for routine, daily practice without intracardiac echocardiography requires expertise in retrograde mapping within the mitral annulus substrate.

Case report

The case concerns a 33-year-old Caucasian man with a history of 5-year recurrent symptomatic supraventricular tachycardia episodes requiring intravenous drugs. The patient was a professional truck driver and required a healthy status for his job. No structural heart diseases or other chronic diseases were noted.

The patient had previously undergone failed right-sided AVNRT slow pathway modification catheter ablation with non-inducibility after 20 applications and isoproterenol infusion. The effective point was found in close relation to the high triangle of Koch with a far-field His signal.

The several arrhythmia recurrences (6 during 3 months prior to the second procedure) after the previous procedure were refractory to beta-blockers and the Valsalva maneuver.

The patient decided to proceed with a repeat procedure. A minimally invasive approach with 2 catheters (4-mm Gold tip non-irrigated catheter Alcath; decapolar diagnostic catheter – Viacath, Biotronik, Berlin, Germany) from femoral access were used with a 3D electroanatomical mapping (EAM) system (Ensite, Navx Velocity, St Jude Medical, St Paul, MN, USA). Due to its instability, the diagnostic catheter was repositioned from the coronary sinus (CS) to the high right atrium and tricuspid annulus. Electrophysiological study (EPS) with pacing from the atrium demonstrated dual AV node physiology with easily and reproducibly inducible narrow complex tachycardia. The tachycardia cycle length (TCL) was 420 ms and the earliest atrial activation was seen at the His position and proximal coronary sinus with septal ventriculoatrial time <70 ms. The diagnosis of typical slow-fast AVNRT and slow pathway conduction was confirmed based on a V-A-V response to overdrive pacing with a corrected post-pacing interval, analysis of the transition zone and parameters of retrograde activation, typical “jump” and sustained slow pathway conduction during incremental atrial pacing with PR>RR.[3,4]

Ablation was initially performed in the right-sided mid-septal region with more than 150 junctional beats but without achieving non-inducibility even with high energy output (standard settings: 60°C, 50 W, 30 s). More than 10 times thermal induction of AVNRT was observed shortly after the beginning of the applications with the high triangle of Koch. The arrhythmia and AV nodal dual physiology remained inducible. Patent foramen ovale was excluded by detailed mapping of the interatrial septum. Therefore, the right femoral artery was punctured to change the approach to retrograde transaortic. Only simple mapping of important landmarks of right and left anatomy was performed (Figure 1). After mapping of the

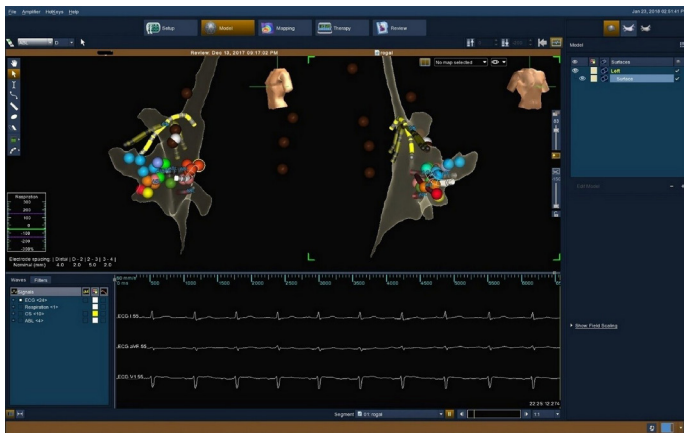


Figure 1. Simplified three-dimensional electroanatomical mapping in LAO 60 and RAO 30 view. Retrograde approach from femoral artery. Blue dots represent right-sided His signal recordings, red and light purple represent ineffective ablation points in triangle of Koch, green dots represent left-sided His signal recordings, brown dots represent aortic arch, dark red represents left-sided successful ablation points on mitral annulus. Shadow of ablation catheter on mitral annulus. Yellow shadow – decapolar diagnostic catheter positioned on tricuspid annulus.

inferoseptal part of the mitral annulus some junctional ectopic beats were produced. Ablation was performed in regions of an A:V signal ratio up to 1:5 with stable monitoring in 3D-EAM. Within the first application junctional rhythms were no longer associated with inducibility of AVNRT. After 12 short applications without thermal induction of AVNRT repeated EPS

showed complete ablation of the slow pathway and arrhythmia remained non-inducible during 20 minutes of observation even after isoproterenol infusion and intensive protocol of pacing from the atrium and ventricle. Total procedure time was 70 minutes with complete exclusion of fluoroscopy and use of a lead apron by medical staff. The patient's status remained uneventful over 3 months after this procedure.

Discussion

We present this case to exemplify the following:

(1) A left-sided approach is infrequently required but may be especially effective for patients with failed AVNRT ablation via traditional approaches.

(2) The ZF approach with retrograde access is safe and effective even for a difficult substrate and close relations to the His-Purkinje network.

(3) Repetitive thermal induction of AVNRT and its lack after effective application with junctional beats could be a marker of effective substrate modification and therefore an additional validation criterion.

To the best of our knowledge, this is the first case demonstrating successful left-sided ablation of typical AVNRT with the ZF approach and retrograde access. Recent large case series and reviews have not reported such a case. Fluoroscopy was used in all published cases of typical and atypical AVNRT (fast-slow and slow-slow) ablation with the left-sided approach.[2,5-8]

It is known that the slow pathway may consist of right- and left-sided branches or connections, which together or separately participate in the tachycardia reentry circuit. Conventional right-sided slow pathway ablation at the inferoseptal to midseptal tricuspid annulus or inside the coronary sinus is effective in the vast majority of cases with slow-fast AVNRT.[3,4]

Through a variety of approaches and ablation techniques (transeptal, retrograde, or via the CS), the left-sided approach should be considered after a failed right-sided approach within the same procedure or after a failed previous procedure.[2,5-8]

There are not, however, any clinical, electrocardiographic or simple electrophysiological predictors for left-sided extension of the slow pathway. Typical invasive detailed mapping of atrial extension of the slow pathway has no pathognomonic features of the A to V ratio. Although retrograde activation in the fast-slow or slow-slow form of AVNRT should be easily diagnosed, mapping of the atrial extensions is clinically difficult in the case of typical slow-fast AVNRT.[6] Eccentric atrial activation of the CS suggesting left-sided atrial node connections of the slow pathway is more common in the atypical forms of AVNRT compared to the typical ones. Moreover, some unusual form of ventricular defect may play a role in this phenomenon.[5,7]

This case also illustrates that application of radiofrequency current can be a provocative method for the induction of AVNRT. This is particularly useful in arrhythmia which is non-inducible using different stimulation protocols including isoproterenol infusion and atropine injection.[4,9] In our previous studies thermal mapping was the only reproducibly

ble technique for induction of AVNRT in up to 2% of cases. However, the incidence of left-sided AVNRT ablation was less than 0.5%.^[3,4]

The introduction of 3D EAM systems has reduced the X-ray exposure significantly for both personnel and patients during the procedures.^[3,10] The ZF approach is reported to be as safe and effective as standard fluoroscopically guided navigation and mapping.^[3,10]

The retrograde approach without the use of intracardiac echocardiography is typically preferred for the left-sided annular substrate after exclusion of patent foramen ovale. Therefore this approach should be used in the majority of cases with left-sided Wolff-Parkinson-White (WPW) syndrome and AVNRT. Some of the rare cases of subvalvular substrate (SP and accessory pathway) may also be ablated from the non-coronary cusp. Routinely using ZF for CA may support this approach even for unfavorable locations and especially in pregnant patients.^[11]

Even rare and difficult anatomy could be effectively treated. Therefore the ZF approach could be used in experienced hands as a standard approach.

References

1. Nakagawa H., Jackman W.M. Catheter ablation of paroxysmal supraventricular tachycardia. *Circulation*. 2007;116:2465–2478.
2. Katritsis D.G., Giazitzoglou E., Zografos T., Ellenbogen K.A., Camm A.J. An approach to left septal slow pathway ablation. *J Interv Card Electrophysiol*. 2011;30:73–79.
3. Stec S, Sledz J, Mazij M, et al. Feasibility of implementation of a “simplified, No-X-Ray, no-lead apron, two-catheter approach” for ablation of supraventricular arrhythmias in children and adults. *J Cardiovasc Electrophysiol*. 2014;25:866–874
4. Sledz J., Labus M., Mazij M. et al. A simplified approach for evaluating sustained slow pathway conduction for diagnosis and treatment of atrioventricular nodal reentry tachycardia in children and adults. *Adv Med Sci*. 2018;63: 249–256 in press.
5. Yamabe H., Tanaka Y., Morihisa K. et al. Multiple forms of atypical atrioventricular nodal reentrant tachycardia with different right-and left-sided retrograde slow pathways. *J Cardiol Cases*. 2010;2:e111–e114.
6. Green J., MD, Aziz Z., MD, M. Nayak H., MD et al. “Left ventricular” AV nodal reentrant tachycardia: Case report and review of the literature. *HeartRhythm Case Rep*. 2016; 2: 367–371.
7. Sorbera C., Cohen M., Woolf P., Kalapatapu S.R. Atrioventricular nodal reentry tachycardia: slow pathway ablation using the transseptal approach. *Pacing Clin Electrophysiol*. 2000;23:1343–1349.
8. Otomo K., Okamura H., Noda T., et al. “Left-variant” atypical atrioventricular nodal reentrant tachycardia: electrophysiological characteristics and effect of slow pathway ablation within coronary sinus. *J Cardiovasc Electrophysiol*. 2006;17:1177–1183.
9. Yamini Sharif A, Vasheghani Farahani A, Davood GR, Kazemisaeid A, Fakhrzadeh H, Ghazanchai F. A new method for induction of atrioventricular nodal reentrant tachycardia in non-inducible cases. *Europace*. 2011;13:1789-92.
10. Yang L, Sun G, Chen X, et al. Meta-analysis of zero or near-zero fluoroscopy use during ablation of cardiac arrhythmias. *Am J Cardiol*. 2016;118:1511-1518.
11. Karbarz D, Stec PJ, Deutsch K, Ślędź J, Stec S. Zero-fluoroscopy catheter ablation of symptomatic pre-excitation from non-coronary cusp during pregnancy. *Kardiol. Pol*. 2017;75:1351